



PATIENT

Grizzly Rodriguez

SPECIES

Feline

BREED

DLH

SEX

Male Neutered

AGE

2 years

WEIGHT

9.3lbs

INTERPRETED BY

Maggie Machen Lamy,
DVM, DACVIM
(Cardiology)

IMAGING PERFORMED BY

Meredith Swart, DVM

HOSPITAL NAME

Swart Veterinary
Imaging

REFERRING VET

Dr. Swart

INVOICE

46263

DATE

12/18/25

PRESENTING CLINICAL SIGNS

History: Loud heart murmur auscultated. Asymptomatic. Labs: WNL.

ECHOCARDIOGRAM FINDINGS

2D, m-mode, color flow and doppler imaging is available. The left ventricular wall is mild to moderately hypertrophied with regions of irregularity. There is a mildly hyperechoic endocardium consistent with fibrosis and ventricular remodeling. Mild papillary muscle hypertrophy. The right ventricle is subjectively normal in size and morphology. There is mild left atrial enlargement present. No right atrial enlargement present. Normal RVOT velocity. The mitral valve is mildly thickened with systolic anterior motion (SAM) seen. Elevated LVOT velocity (dynamic profile). There is mild eccentric mitral regurgitation present secondary to SAM. No other obvious valvular regurgitation is present. There is no pericardial effusion noted. No pleural effusion appreciated. No cardiac tumors visualized.

CARDIAC CHART

FELINE CARDIAC PARAMETERS	BODY WEIGHT (kg)	HR (BPM)	IVSd (cm) (Moise, Pipers)	LVIDd (cm) (Moise, Pipers)	LVWd (cm) (Moise, Pipers)	FS (%)	EF (%)
NORMAL PARAMETER	-----	150-240	0.35-0.55	<2 (mean 1.5)	3.5-0.55	35-67	80-100
PATIENT	4.2	NM	0.65	1.1	0.62	51	85
FELINE CARDIAC PARAMETERS	LA/AO (Boon)	LA/AO HEART BASE (Swe) (Abbott)	LA 2D short axis Base view (cm) (Abbott)		LVOT VEL (m/s)	RVOT VEL (m/s)	E max (m/s)
NORMAL	<1.5	<1.3	<1.2		<1.6	<1.3	<0.9
PATIENT	NM	1.5	1.4		>4.0	2.0	NM

**Note: All measurements based upon multi-modal images and methods. An average value is reported.*
Adapted from June Boon, Veterinary Echocardiography, 1998
Abbott J & MacLean H JVIM 2006;20: 111-119, Moise et al. Am J Vet Res 47:1476, 1986. Pipers et al. Am J Vet Res 40:882, 1979.

INTERPRETATION OF THE FINDINGS & FURTHER RECOMMENDATIONS

The diagnosis is hypertrophic obstructive cardiomyopathy (HOCM). This indicates LV hypertrophy (mild to moderate in this case) with a dynamic LVOT obstruction (SAM) and secondary MR. Mital valve dysplasia would be an alternative diagnosis depending on murmur chronicity. Regardless, there is mild left atrial dilation, indicating the risk of spontaneous CHF and/or a thrombotic event, while currently low, may be elevated in the future. A screening BP and T4 are recommended every 6 months, as both can exacerbate disease. No additional issues are seen.

While no medications have been shown to definitively alter long term outcome at this stage of disease, atenolol is often initiated to decrease the outflow obstruction. Given the degree of hypertrophy and mild LA dilation, consider initiate at this time as below. If there is difficulty medicating at home, an alternative approach would be closely monitoring for progression in the next 6 months. Discussion with the owner is advised.



PATIENT

Grizzly Rodriguez

SPECIES

Feline

BREED

DLH

SEX

Male Neutered

AGE

2 years

WEIGHT

9.3lbs

INTERPRETED BY

Maggie Machen Lamy,
DVM, DACVIM
(Cardiology)

IMAGING PERFORMED BY

Meredith Swart, DVM

HOSPITAL NAME

Swart Veterinary
Imaging

REFERRING VET

Dr. Swart

INVOICE

46263

DATE

12/18/25

Prognosis is guarded, given the highly variable rates of progression with subclinical feline cardiomyopathy. Many cats will remain asymptomatic for a period of years, while others progress to clinical compromise sooner. Close monitoring for progressive LA dilation in the future will help determine long term outcome.

Anesthetic risk is considered mildly elevated; however, judicious fluid administration is advised if needed with careful monitoring to screen for fluid overload. A reasonable protocol includes opioid/benzodiazepine premedication, propofol induction, isoflurane maintenance. Avoid ketamine, telazol, acepromazine and Dexdomitor. Additionally, drugs that stimulate heart rate should be avoided unless clinically necessary (glycopyrrolate, atropine).

Risk for complication with steroid or fluid use typically follows LA dilation, which in this case is mildly elevated. If needed, monitoring of RR/RE is advised particularly in the initiation phase.

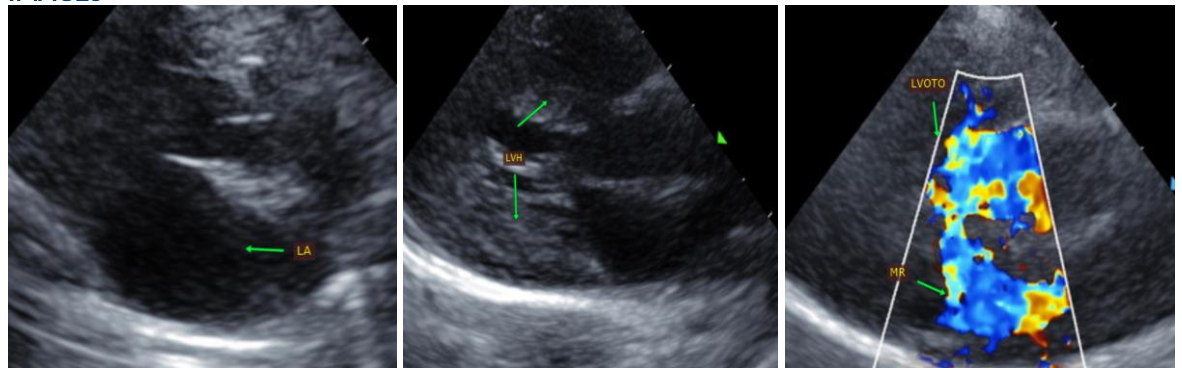
Monitor at home for any respiratory signs or blood clot events (neurologic change, paralysis, etc.) in the future.

PLAN

Screening BP/T4. Administer titrating dose of atenolol: 25mg tablets; Give ¼ tab once daily. Recheck heart rate in 1-2 weeks with target stressed rate of 140-160bpm 12-24 hours post-administration. Increase as needed until target reached.

Recommend recheck echocardiogram in 6 months to assess for progression, sooner if clinical issues arise.

IMAGES



The information and recommendations provided are based on the images presented by the referring veterinarian. No evaluation can be communicated regarding pathology that was not visible in the image/video clips provided.

Thank you for this referral. This report was generated using transcription software, and minor dictation errors may be present. If the clinical or image interpretation does not parallel your findings or if I can be of any further assistance, please contact me.

Maggie Machen Lamy, DVM
Diplomate of the American College of Veterinary Internal Medicine (Cardiology)
info@sonopath.com